

## TECHNICAL NOTE

Manfred N. Hochmeister,<sup>1</sup> M.D.; Margaret Whelan,<sup>2</sup> B.S., R.N.; Urs V. Borer,<sup>1</sup>; Christian Gehrig,<sup>1</sup> B.S.; Sabina Binda,<sup>1</sup>; Andrea Berzlanovich,<sup>3</sup> M.D., Elisabeth Rauch,<sup>4</sup> M.D., and Richard Dirnhofner,<sup>1</sup> M.D.

# Effects of Toluidine Blue and Destaining Reagents Used in Sexual Assault Examinations on the Ability to Obtain DNA Profiles from Postcoital Vaginal Swabs

**REFERENCE:** Hochmeister MN, Whelan M, Borer UV, Gehrig C, Binda S, Berzlanovich A, Rauch E, Dirnhofner R. Effects of toluidine blue and destaining reagents used in sexual assault examinations on the ability to obtain DNA profiles from postcoital vaginal swabs. *J Forensic Sci* 1997;42(2):316–319.

**ABSTRACT:** Toluidine blue is an important tool to detect and document genital and perianal injuries following sexual assault. Application of toluidine blue dye and its subsequent removal from unstained areas by means of a destaining reagent, such as diluted acetic acid or a lubricant has been shown to increase the detection rate of posterior fourchette lacerations from 16% to 40% in adult rape victims. Currently, limited information on toluidine blue positive findings in sexually active control groups imposes some limitation on the interpretation of these injuries. Because injuries could otherwise be attributed to improper handling of an examination speculum or the improper insertion of the examining finger, the toluidine blue test should be performed prior to any digital or speculum examination and thus prior to the collection of forensic evidence. For forensic DNA identity testing, it becomes pertinent to determine whether toluidine blue and the destaining reagents used in a sexual assault examination have an adverse effect on the recovery of high molecular weight DNA from postcoital vaginal swabs and thereby have an impact on restriction fragment length polymorphism (RFLP) analysis or PCR-based tests. It is known that some of the lubricants used can have a destructive effect on sperm motility. In order to investigate the potential effects, postcoital vaginal swabs were taken 6 h after sexual intercourse and exposed directly to 1% toluidine blue in aqueous solution, 1–10% acetic acid, and various surgical and vaginal lubricants. Subsequently, the DNA was isolated and DNA identity typing (RFLP and PCR-based) was performed. The results demonstrate, that these reagents have no negative effect on the ability to obtain DNA profiles, either RFLP or PCR-based, from shallow and deep vaginal swabs. The quantity and quality of extractable high molecular

weight DNA obtained was comparable with that from uncontaminated postcoital vaginal swabs. RFLP patterns and PCR-based typing results on the D1S80, HUMTH01, TPOX, and CSF1PO loci were consistent with the uncontaminated control swabs and the corresponding whole blood samples of the donors. Therefore, evidentiary material inadvertently contaminated with these reagents can be successfully typed.

**KEYWORDS:** forensic science, sexual assault, vaginal swabs, perineal lacerations, toluidine blue, acetic acid, lubricants, DNA, restriction fragment length polymorphism, polymerase chain reaction, genetic typing, D2S44, D4S139, D5S110, D10S28, TH01, TPOX, CSF1PO

There are more than 90,000 rape cases brought to the attention of official investigators per year in the United States. Unfortunately, many rape victims do not have sufficient signs on physical examination to support their history (1,2). In a study of 2190 female rape victims in Washington, D.C., only 20% had signs of trauma or the corroborative evidence of a witness to indicate that sexual assault has occurred (3), in another study of 117 cases of female rape, only 19% had genital lacerations that could be used to substantiate the victim's claim (4). Other authors have noted a less than 15%–20% incidence of detectable genital trauma in the examination of alleged rape victims (3,5,6,7,8,9,10).

In an effort to collect more objective evidence of traumatic intercourse, Lauber and Souma, in 1982, developed a simple dye test to help detect lacerations in the genital area (11). Prior to the insertion of a speculum or the examining fingers, a 1% aqueous solution of toluidine blue is applied to the posterior fourchette and the perineum using cotton tip applicators. After drying for a few seconds, excess dye is removed either by spraying with 1% acetic acid or by gently wiping with a cotton ball moistened with lubricating jelly. Linear areas retaining a deep royal blue stain are interpreted as positive (Fig. 1).

Toluidine blue, a general nuclear stain, was first used by Richard, in 1963, for outlining areas of dysplasia and carcinoma in situ of the cervix (12). Niebel, in 1964, has used toluidine blue in the oral cavity to delineate neoplastic areas (13). Collins et al., in 1966, described its use for the selection of biopsy sites in patients with vulvar disease, such as lichen sclerosis or carcinoma (14). Besides its staining properties, the dye is used intravenously as

<sup>1</sup>Research scientists, and director, respectively, Institute of Legal Medicine, University of Berne, Switzerland.

<sup>2</sup>Forensic nurse examiner, Pomerado Hospital, Poway, CA.

<sup>3</sup>Medical examiner, Institute of Legal Medicine, University of Vienna, Austria.

<sup>4</sup> Medical examiner, Institute of Legal Medicine, University of Munich, Germany.

Disclaimer: The names of commercial manufacturers are provided for identification only and inclusion does not imply endorsement by the authors.

Received 4 June 1996; and in revised form 17 July 1996; accepted 2 Aug. 1996.

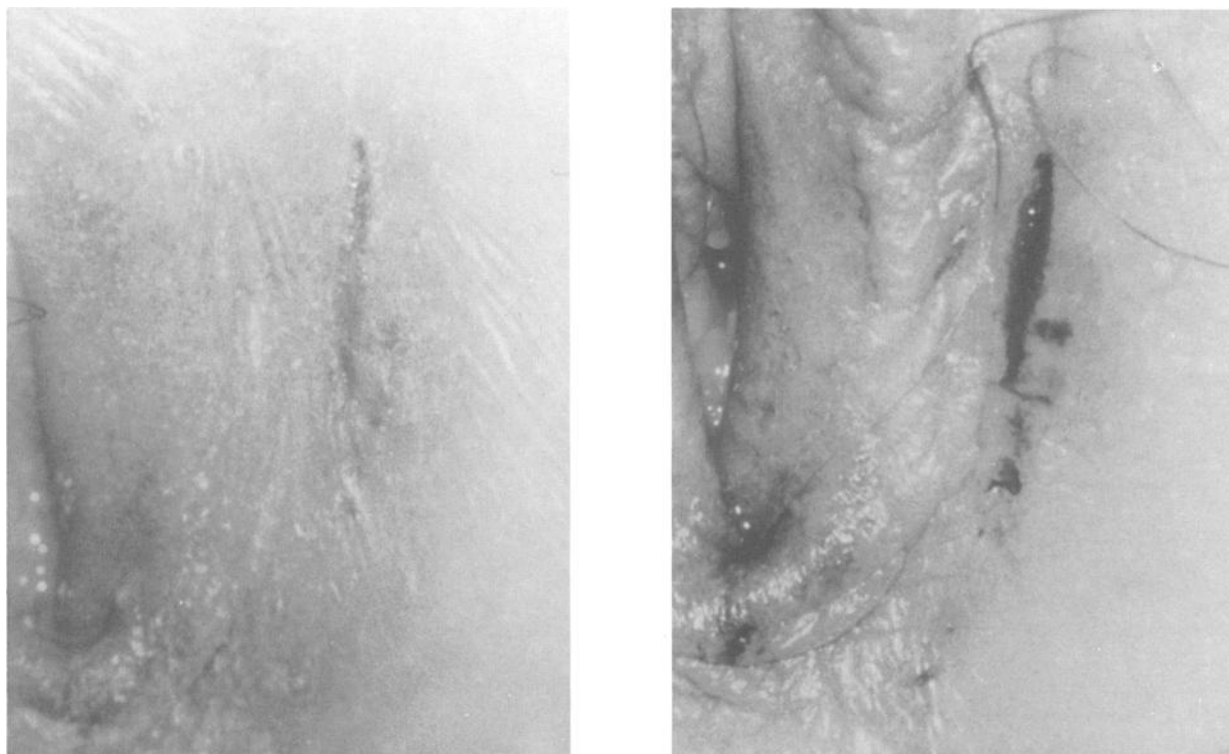


FIG. 1—Left: Genital area before application of toluidine blue. A linear laceration is visible. Right: Toluidine blue-highlighted laceration after application of the dye and destaining by spraying with 1% acetic acid.

an antidote for methemoglobinemia. Lauber and Souma, in 1982, (11) McCauley et al., in 1986 (15), and Bays and Lewman, in 1992 (16), evaluated the test in victims of sexual abuse. As used in vivo, the stain result depends on the presence or absence of a nucleated cell population at the exposed surface. Normal vulvar skin surface contains no nuclei and will not bind this dye. A positive stain is seen in areas of excoriation and laceration, because these areas expose deeper dermis that contains nuclei. Toluidine blue clearly highlights genital and perianal lacerations that were questionable or not seen before dye application.

A positive toluidine blue test is supportive though not conclusive evidence of sexual assault. Because of the appearance of unequivocal lacerations after consenting intercourse, the usefulness of this test in evaluation of rape victims may be challenged. However, consent for coitus does not preclude trauma, just as absence of trauma does not provide proof of consent. Vaginismus and improper coital technique may be responsible for superficial lacerations in willing participants in intercourse. A study by Lauber and Souma showed that trauma is rare in consenting intercourse. Only 4% of adult women displayed posterior fourchette lacerations following voluntary intercourse, and all of those complained of dry and painful intercourse (11). McCauley reported that 10% of a control group of consenting women who had voluntary intercourse within 48 h of examination had lacerations noted with toluidine blue application. McCauley et al. showed that adult rape victims are 16 times more likely to have toluidine blue highlighted lacerations than adult control individuals following voluntary intercourse (15). The same authors report, that the presence of posterior fourchette lacerations in a child less than 10 years of age is an important and perhaps specific physical finding and strongly suggestive of sexual abuse. The incidence of lacerations in this sexually abused group was 33%, whereas none of the control children had any

lacerations detected (15). However, in the adolescent population (11 to 18 years of age) the presence of posterior fourchette lacerations is not diagnostic of sexual abuse. Posterior fourchette lacerations were as common in the sexually active adolescent population as in the sexually abused adolescent population (15). This may reflect the tense pubococcygeus muscle in the adolescent. All of the laceration positive control adolescents complained of painful intercourse.

In the use of the test for identification of trauma, it is also important for the examiner to be aware of positive test results from other causes. These are inflammatory as well as benign or malignant vulvovaginal disease (16,17). A positive test in this circumstances demonstrates a more diffuse pattern of uptake.

It is further important to emphasize that the absence of detectable lacerations is common in sexually abused patients. The absence of lacerations in no way precludes the possibility of sexual abuse, neither does the presence of lacerations implicate the penis as the inflicting agent; fingers, foreign objects, even improperly handled examining specula may be indicated. As Lauber and Souma state, this emphasizes the importance of performing the toluidine blue test before vaginal digital or speculum examination (11). The significance of toluidine blue positive findings, such as superficial lacerations, may be questioned in court, if the speculum portion of the genital examination or an insertion of the examining finger was performed before the dye application. Toluidine blue dye significantly increases the detection of posterior fourchette lacerations from 16% to 40% in adult rape victims (11), from 4% to 28% in adolescent sexually abused patients, and from 16.5% to 33% in pediatric sexually abused patients (15). The same applies to the examination and evidence collection in the perianal area and rectum.

Although the dye and destaining reagents are applied externally

and not intravaginally, it may be a concern, that they have deleterious effects on DNA typing results, if swabs are inadvertently contaminated. Therefore it is essential to be aware of the effects that can be produced by toluidine blue and the most common used destaining reagents. Toluidine blue has been found to be spermicidal (11), and the spermicidal property of some surgical and vaginal lubricants is well recognized (19,20,21,22,23). Apart from the fact, that toluidine blue has not been found to affect acid phosphatase levels *in vitro* (11), we are aware of no information relating to the possible effects of these reagents to the typing of DNA extracted from postcoital swabs.

The purpose of the present study was to determine whether or not toluidine blue and various destaining reagents used in sexual assault examinations would have an adverse effect on the recovery of the high molecular weight DNA from semen recovered from postcoital vaginal swabs and thereby have an impact on restriction fragment length polymorphism (RFLP) analysis, or on PCR-based typing results.

### Material and Methods

The following reagents were used in this study: 1% toluidine blue in aqueous solution (Chroma-Gesellschaft, Köngen/N., Germany), 1–10% acetic acid (Merck), Astroglide (Biofilm, Inc. Vista, CA, USA), K-Y Jelly (Johnson & Johnson, Skillman, NJ, USA), Surgilube (Altana Inc., Melville, NY, USA), Echotrak, Omnigel, Sonotrak, (all from Echo Ultrasound, Reedsville, PA, USA), Instilla Gel, Endosgel (both from Farco-Pharma, Köln, Germany), Cathejell (Montavit Ges.m.b.H., Absam, Austria), Lubo Gel (Kramer-Pharma, Lausanne, Switzerland), Gleitgelen (Wolf GmbH & Co., Bielefeld, Germany), Atarost Vaginal Lubricant (Twistingen, Germany).

Whole blood samples, drawn by venipuncture, were collected from five male and five female donors and stored in EDTA tubes. Control (reagent free) postcoital vaginal swabs were collected on cotton-tip swabs six hours after sexual intercourse from the five female donors (14 swabs per person). Immediately after collection, each reagent was added to a swab (one reagent per swab). Special care was taken to ensure that the entire swab was covered with the reagent. After air drying, samples were stored at  $-20^{\circ}\text{C}$  until DNA analysis was carried out. Each swab was subjected to a differential DNA extraction as previously described (24,25,26). The quantity of human DNA in all samples was determined using the slot-blot method described by Wayne et al., and Walsh et al. (27,28), and by ethidium bromide agarose gel electrophoresis. RFLP-based loci D2S44, D4S139, D5S110, D10S28, and PCR-based loci TH01, TPOX, CSF1PO, were typed in this analysis according to methods previously described (29,30).

### Results

High molecular weight DNA could be recovered from all postcoital vaginal swabs exposed to 1% toluidine blue in aqueous solution, 1–10% acetic acid, and the various vaginal and surgical lubricants, as well as from the corresponding reagent-free control swabs and whole blood samples. The quantity of human DNA recovered from the postcoital vaginal swabs exposed to the different reagents as determined by slot-blot analysis did not show any differences compared with the control swabs, neither were there any noticeable differences in the quality of recovered DNA between the postcoital vaginal swabs exposed to the different reagents and the control vaginal swabs, based on ethidium bromide agarose gel electrophoresis.

The RFLP profiles from control swabs and contaminated swabs were similar in all cases for all loci analyzed (data not shown). Based on the observed measurement error, the reagents had no effect on RFLP results (the range of all measurements for RFLP loci D2S44, D4S139, D10S28, and D17S26 was: Male fraction of control swabs to male fraction of contaminated swabs:  $\pm 0.51\%$ , female fraction of control swabs to female fraction of contaminated swabs:  $\pm 0.59$ ).

All samples were also subjected to PCR and typed for D1S80, HUMTH01, TPOX, and CSF1PO. The types derived from the contaminated swabs were consistent with those of the corresponding control vaginal swabs (Fig. 2) and whole blood samples from the donors. No false positive or false negative results were observed.

### Discussion

In addition to the identification of an assailant by means of DNA typing in a case of sexual assault, documentation of any signs of trauma on a victim's body can be significant. The simple and inexpensive toluidine blue test is an appropriate method for providing physical evidence in cases of suspected sexual abuse. However, currently some limitations exist on the interpretation of toluidine blue positive findings as evidence of sexual assault, because there are only two studies that address the significance of the results by studying control subjects of different age groups

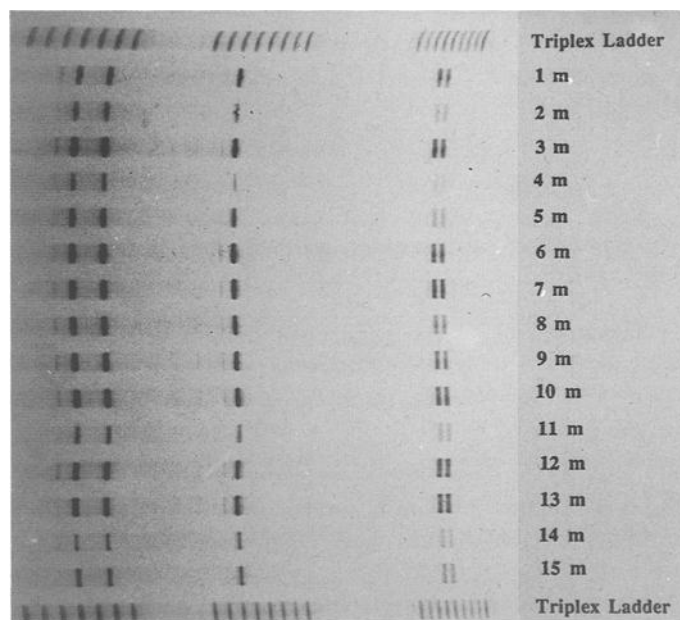


FIG. 2—Silver-stained DNA profiles of the three simultaneously amplified STR loci TH01, TPOX, and CSF1PO demonstrating that toluidine blue and different destaining reagents have no effect on the ability to obtain PCR-based DNA profiles from postcoital vaginal swabs. Each lane presents genetic information for three loci. The profiles show the male fractions of vaginal swabs after exposure to: Astroglide (1 m), Echotrak (2 m), Omnigel (3 m), Sonotrak (4 m), K-Y Jelly (5 m), Instilla Gel (6 m), Surgilube (7 m), Cathejell (8 m), Lubo Gel (9 m), Endosgel (10 m), Gleitgelen (11 m), Atarost Vaginal Lubricant (12 m), 10% Acetic acid (13 m), Toluidine blue in 1% aqueous solution (14 m). The male fraction of the untreated control swab is shown in lane 15 (15 m). The STR ladder alleles (# of repeats) from left to right are: TH01: 5,6,7,8,9,10,11; TPOX: 8,9,10,11,12; CSF1PO: 7,8,9,10,11,12,13,14,15. The typing results from the sperm cell fraction of the postcoital vaginal swabs are: for TH01; for TPOX; for CSF1PO; and for the K562 allelic control DNA: 9.3,9.3 for TH01; 8.9 for TPOX; and 9,10 for CSF1PO.

(11,15). This does not reduce the overall value of the test to detect and document genital injuries present at the time of examination regardless of the subsequent significance.

The test currently enjoys only limited use in Europe and the United States. By surveying hospitals and emergency departments that conduct sexual assault examinations, we discovered that the main reason for not using the toluidine blue test is a general lack of knowledge of its practicability in sexual assault examinations. Further, the necessary reagents are not provided in any sexual assault evidence collection kit currently distributed. In addition, some concern was raised about possible deleterious effects of the reagents on DNA typing results. For the toluidine blue test to become more used in sexual assault examinations, education about its value for the detection and documentation of genital injuries will need to be done. In addition, it would be desirable to gain more information regarding toluidine blue positive findings by studying control subjects. It is pertinent for the forensic science community to become aware of the possible effects the reagents on DNA typing results obtained from postcoital vaginal swabs, if swabs are contaminated inadvertently. Prior to this study, it was unknown whether or not recovered DNA inadvertently exposed to toluidine blue, 1–10% acetic acid or various lubricants used in sexual assault examinations might have been degraded. The data here demonstrate that DNA from sperm and nonsperm cells exposed to these reagents are still amenable to RFLP and PCR-based analysis for identity typing purposes. Furthermore, different brands of lubricants, which are not only used for destaining, but could be present as contaminants on vaginal swabs (e.g., from the insertion of a lubricated speculum), did not interfere with subsequent RFLP or PCR-based analyses.

## References

- Paul D. The medical examination of the live rape victim and the accused. *Leg Med Annual* 1977;139–53.
- Massey J, Gracie C, Emich J. Management of sexually assaulted females. *Obstet Gynecol* 1971;38:29–36.
- Hayman CR, Lanza C, Fuentes R. Rape in the District of Columbia. *Am J Obstet Gynecol* 1972;113:91.
- Everett RB, Jimerson GK. The rape victim—a review of 117 consecutive cases. *Obstet Gynecol* 1977;50:88.
- Zuspan FD, Bernstein GS, Burks JL. Alleged rape—an invitational symposium. *J Reprod Med* 1974;12:133.
- Soules MR, Stewart SK, Brown KM. The spectrum of alleged rape. *J Reprod Med* 1978;20:33.
- Massey JB, Garcia CR, Emich JP. Management of sexually assaulted females. *Obstet Gynecol* 1971;38:1.
- Cantwell H. Vaginal inspection as it relates to child sexual abuse in children under age 13. *Child Abuse Negl* 1983;7:171–6.
- Rimza ME, Niggemann EH. Medical evaluation of sexually abused children: a review of 311 cases. *Pediatrics* 1982;69:8–14.
- Scherzer L, Lala P. Sexual offenses committed against children. *Clin Pediatr* 1980;19:679–85.
- Lauber AA, Souma ML. Use of toluidine blue for documentation of traumatic intercourse. *Obstet Gynecol* 1982;60:622–48.
- Richart RM. A clinical staining test for the in vivo delineation of dysplasia and carcinoma in situ. *Am J Obst Gynecol* 1963;86:703.
- Niebel HH, Chomet B. In vivo staining test for delineation of oral intraepithelial neoplastic change. *J Amer Dentist Assoc* 1964;68:801.
- Collins CG, Hansen LH, Theriot E. A clinical stain for use in selecting biopsy sites in patients with vulvar disease. *Obstet Gynecol* 1966;28:158–63.
- McCauley J, Gorman RL, Guzinski G. Toluidine blue in the detection of perineal lacerations in pediatric and adolescent sexual abuse victims. *Pediatrics* 1986;78:1039–43.
- Bays J, Lewman LV. Toluidine blue in the detection at autopsy of perineal and anal lacerations in victims of sexual abuse. *Arch Pathol Lab Med* 1992;116:285–6.
- Friedrich EG. Toluidine blue test. Vulvar disease—Major problems in obstetrics and gynecology 1976;9:30–4 Friedman EA, editor Philadelphia, Saunders.
- Bays J, Jenny C. Genital and anal conditions confused with child sexual abuse trauma. *AJDC* 1990;144:1319–22.
- Tagatz GE, Okagaki T, Sciarra JJ. The effect of vaginal lubricants on sperm motility and viability in vitro. *Am J Obstet Gynecol* 1972;113:88–90.
- Frishman GN, Luciano AA, Maier DB. Evaluation of astroglide, a new vaginal lubricant: effects of length of exposure and concentration on sperm motility. *Fertil Steril* 1992;58:630–2.
- Goldenberg RL, White R. The effect of vaginal lubricants on sperm motility in vitro. *Fertil Steril* 1975;26:872–3.
- Schoeman MN, Tyler JPP. Effects of surgical lubricants on semen analysis. *Clin Reprod Fertil* 1983;2:275–81.
- Miller B, Klein TA, Opsahl MS. The effect of a surgical lubricant on in vivo sperm penetration of cervical mucus. *Fertil Steril* 1994;61:1171–3.
- Gill P, Jeffreys AJ, Werrett DJ. Forensic application of DNA fingerprints. *Nature* 1985;318:577–9.
- Giusti A, Baird M, Pasqual S, Balazs I, Glassberg J. Application of deoxyribonucleic acid (DNA) polymorphisms to the analysis of DNA recovered from sperm. *J Forensic Sci* 1986;31:409–17.
- GenePrint™ DNA Typing—Technical Manual, 1989, Promega Corporation Madison, WI.
- Waye JS, Presley LA, Budowle B, Shuttler GG, Fournery RM. A simple and sensitive method for quantifying human genomic DNA in forensic specimen extracts. *BioTechniques* 1986;7:852–5.
- Walsh PS, Varlaro J, Reynolds R. A rapid chemiluminescent method for quantitation of human DNA. *Nucl Acids Res* 1992;20:5061–5.
- Budowle B, Baechtel FS. Modifications to improve the effectiveness of restriction fragment length polymorphism typing. *Appl Theor Electrophoresis* 1990;1:181–7.
- Promega, Technical Manual, GenePrint™ STR systems, 1994, Promega Corporation, Madison, WI, USA.

Additional information and reprint requests:  
 Manfred N. Hochmeister, M.D.  
 Institute of Legal Medicine  
 Buehlstrasse 20, CH-3012 Bern, Switzerland